

## Clinico-Radiological Case Presentation

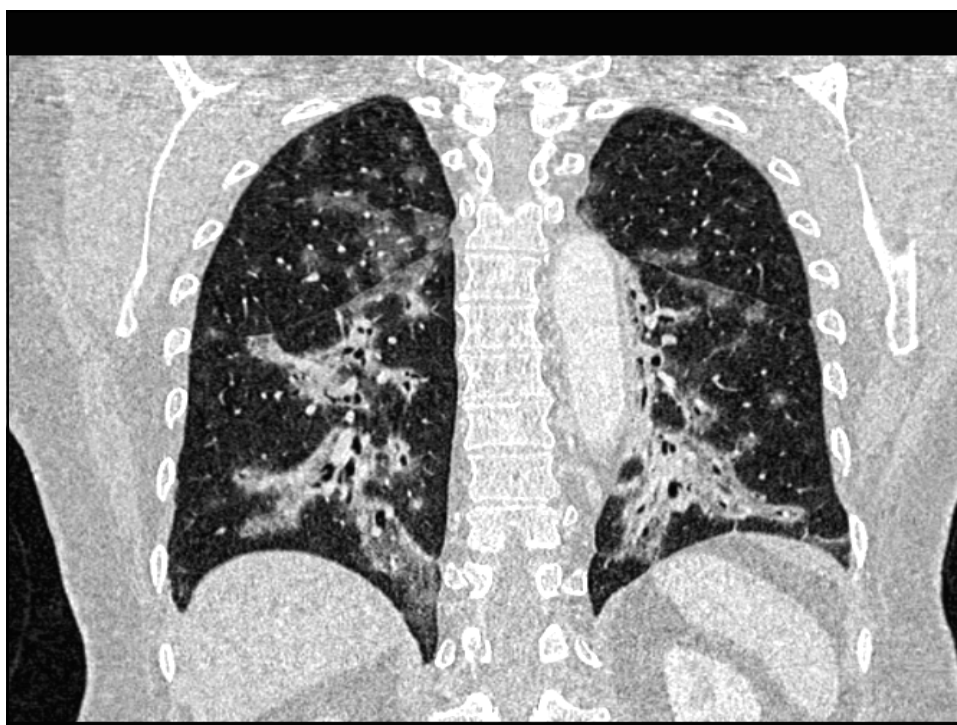
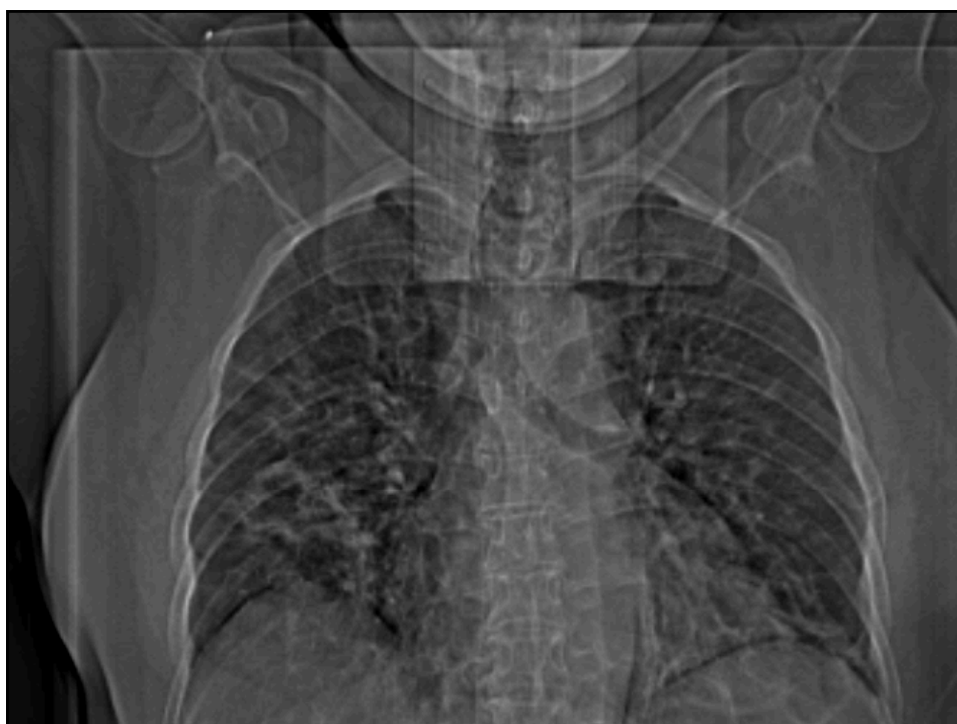
Dr Ashok MANRAJ  
Radiologist

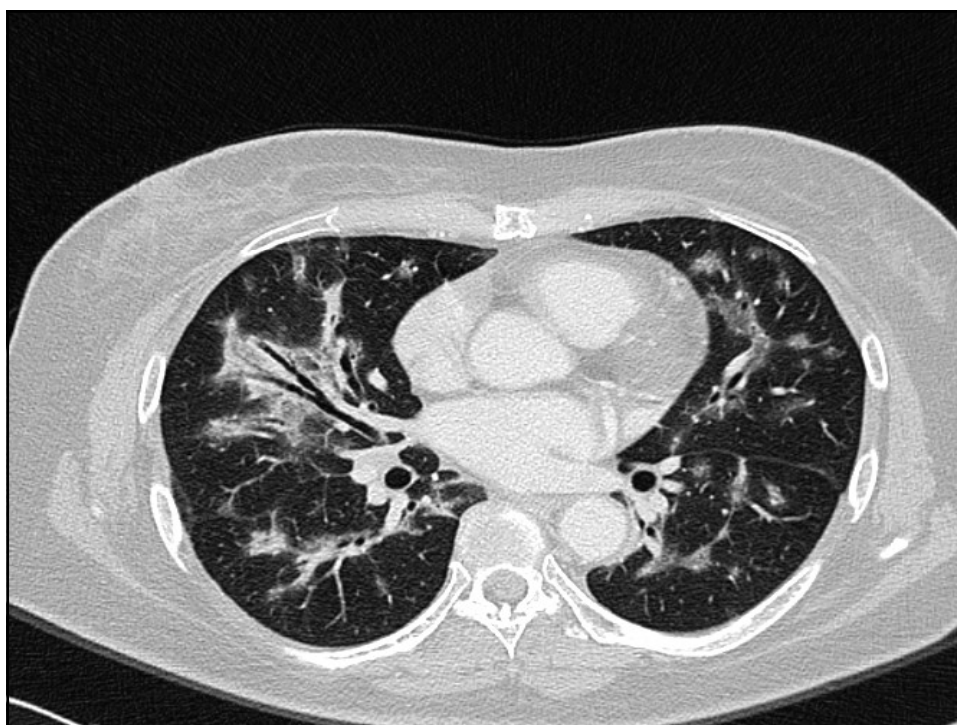
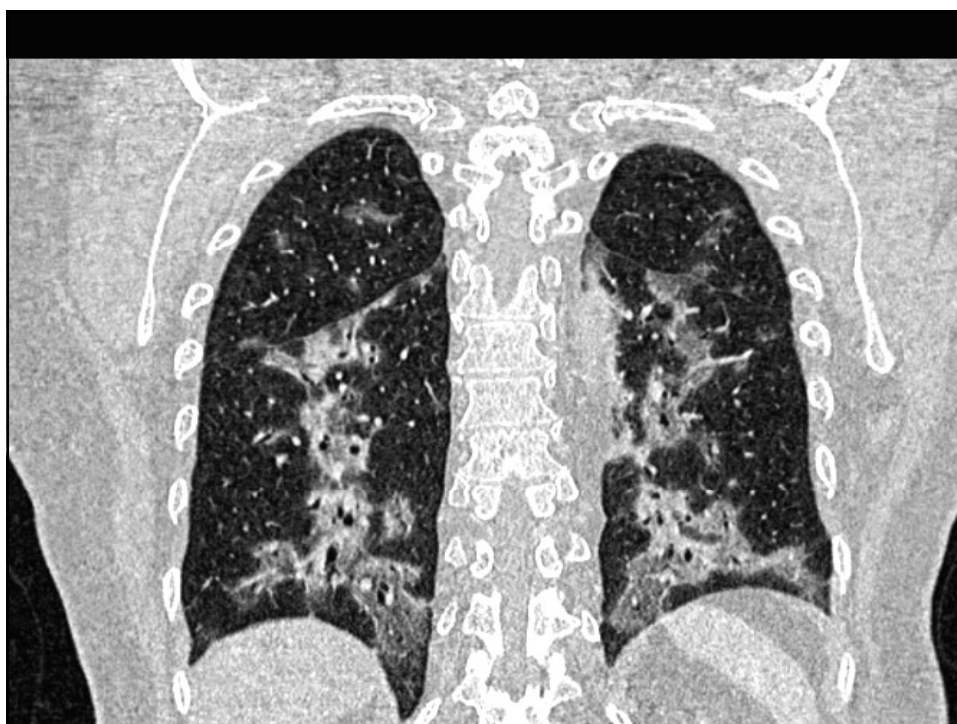
Medical Update session

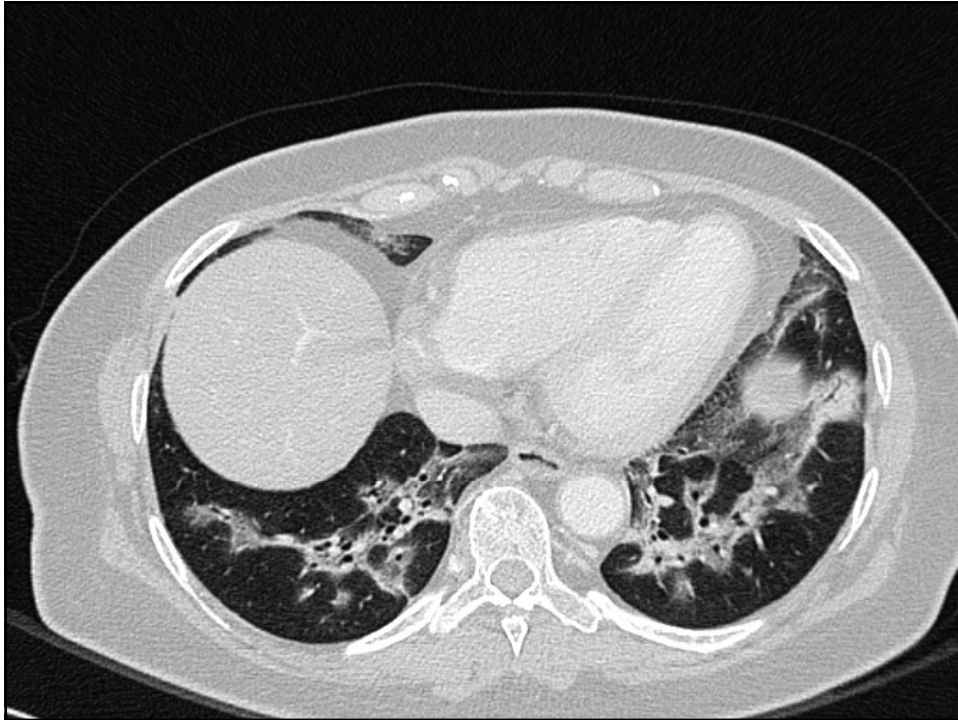
8<sup>th</sup> April 2009

### CASE No 1

- 66 yrs old female diabetic patient
- Flu-like symptoms since Sept 08
- Not responding to antibiotics
- Lab tests
- Chest X-ray : bilateral inhomogeneous interstitial infiltrates
- HRCT scan of chest in Dec 08





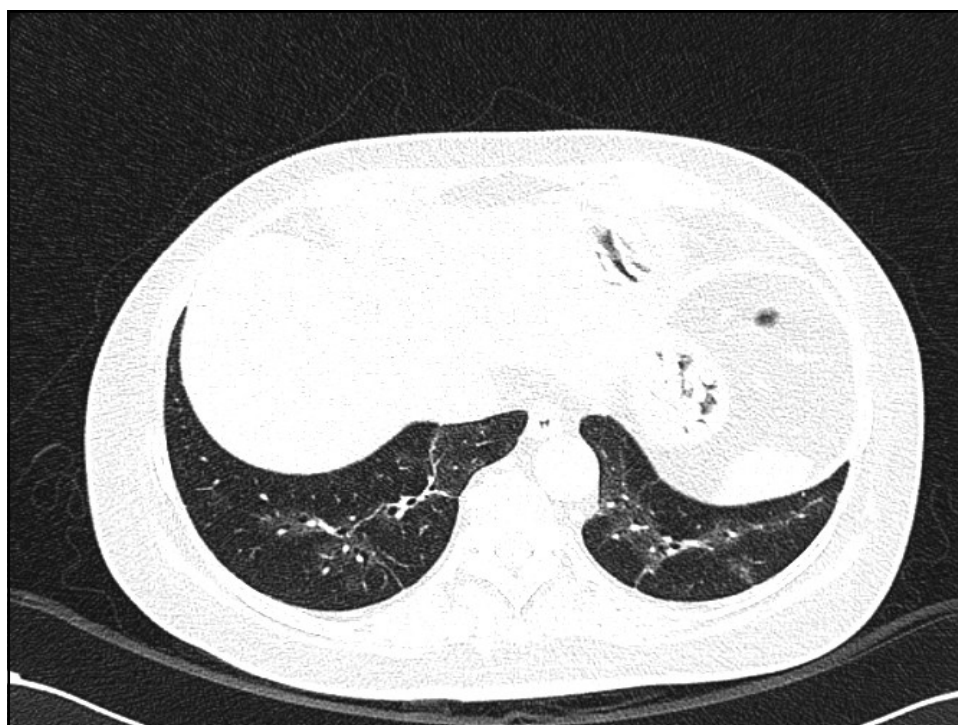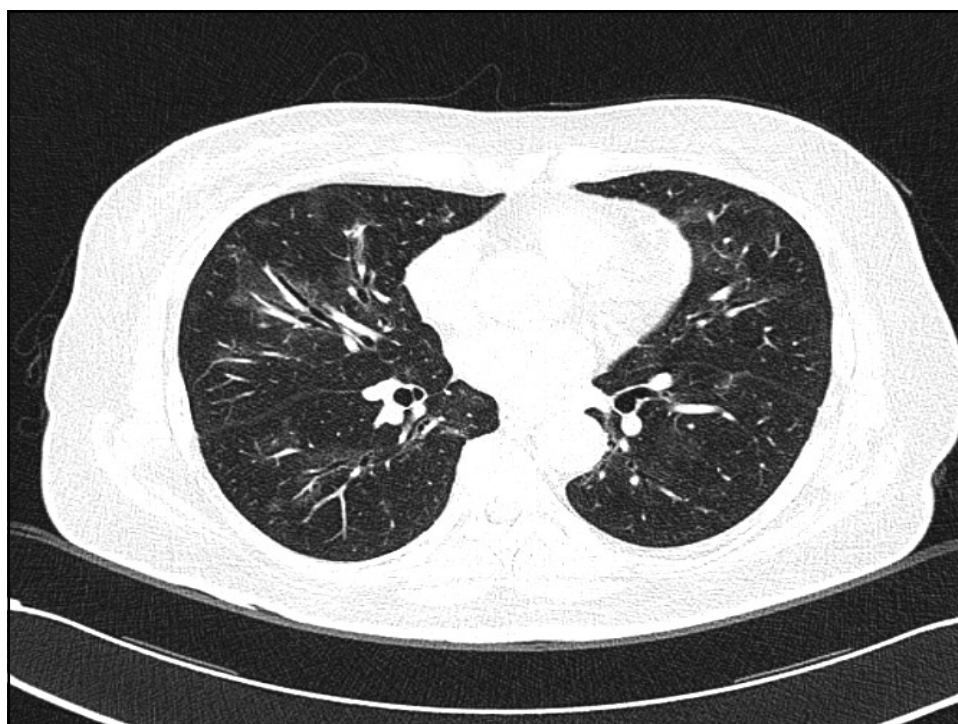


### **Broncho-centric pattern**

- Tuberculosis (endobronchial spread)
- Infectious bronchiolitis
- Hypersensitivity pneumonitis
- Histiocytosis
- BOOP
- Pneumoconiosis
- Aspiration pneumonia
- Centri-lobular emphysema
- Lymphoma
- Non-specific interstitial pneumonitis

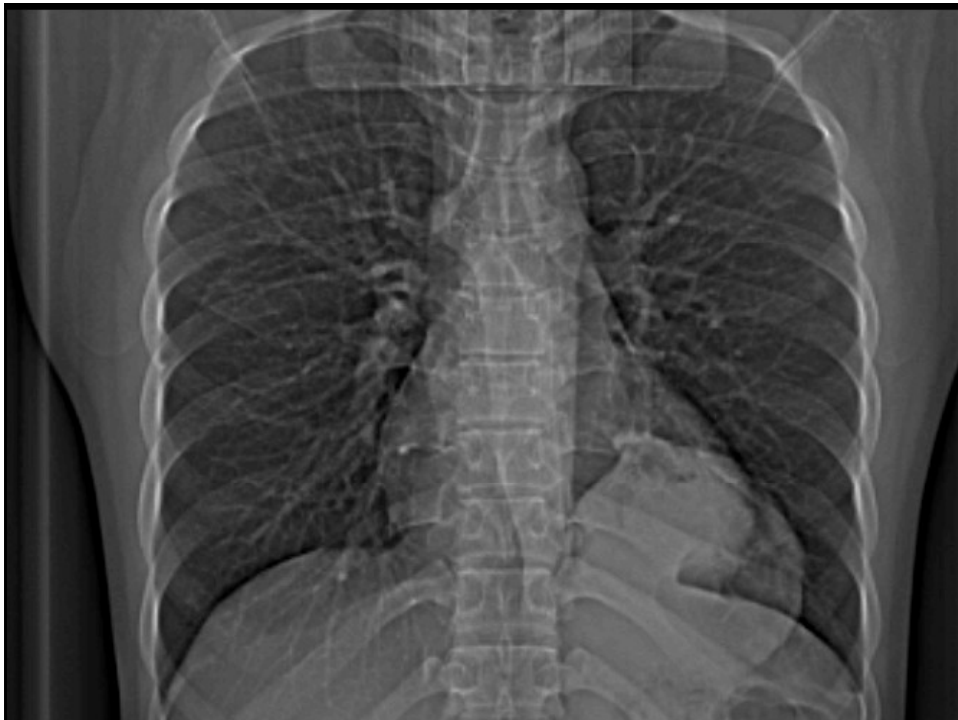- HRCT scan of chest
- IMP: **Bronchiolitis obliterans with organizing pneumonia (BOOP)**
- Diff.diagnosis : Non-specific interstitial pneumonitis and lymphoma

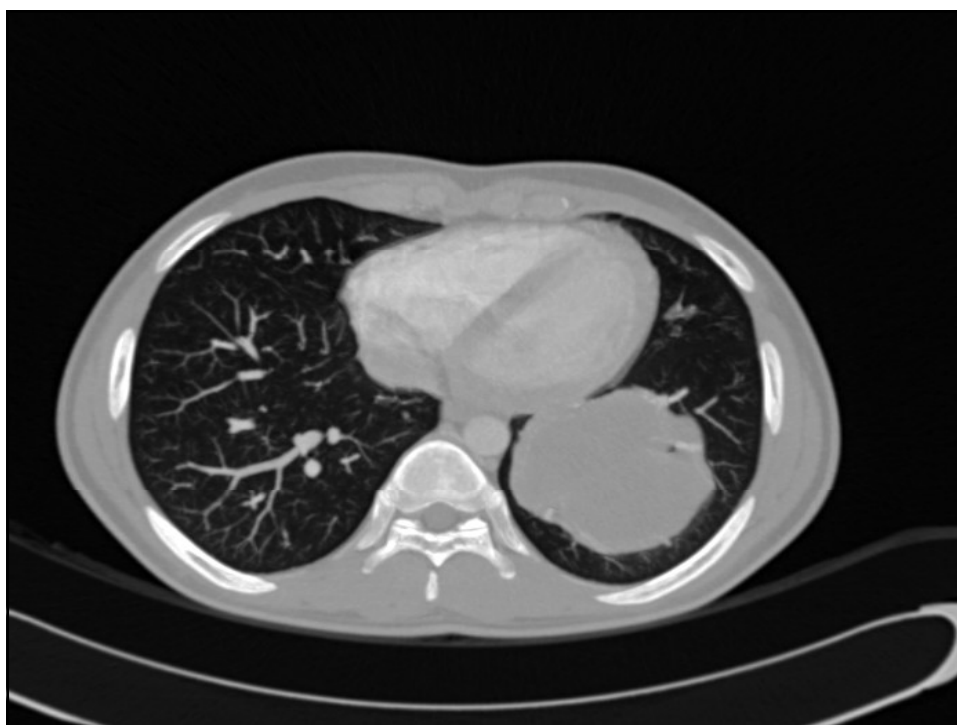
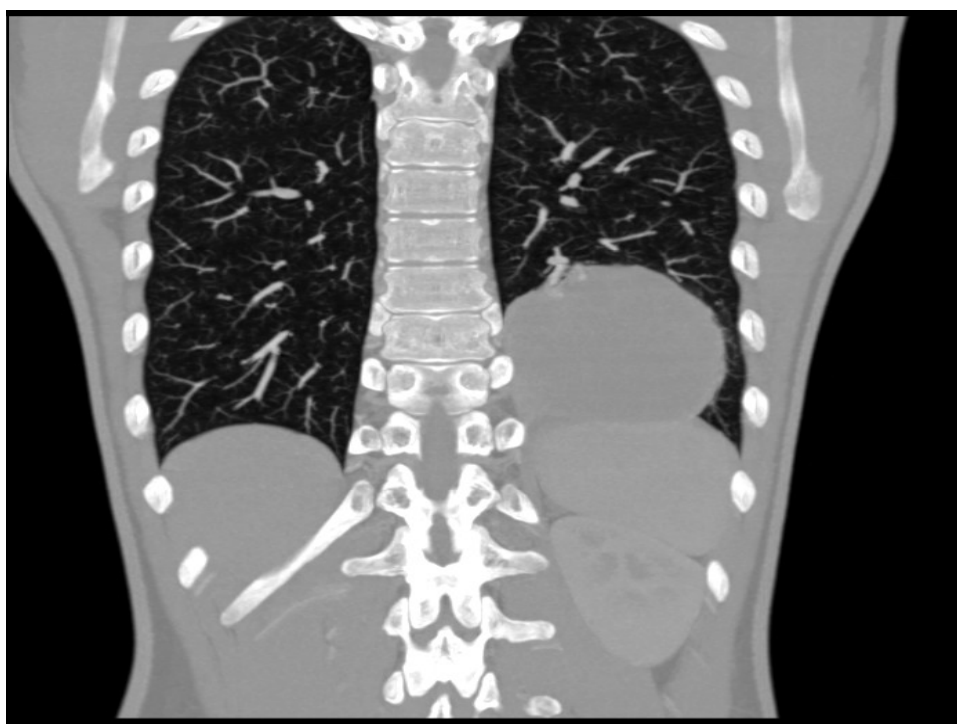
- Admitted in Fortis Hospital (Delhi) in Dec 08
- Transbronchial lung biopsy :  
*histology inconclusive*
- Thoracoscopic lung biopsy :  
*histology : intra-alveolar organising exudates without evidence of vasculitis nor fibrosis*
- Clinical/HRCT/Histology diagnosis  
*Idiopathic bronchiolitis obliterans with organising pneumonia (BOOP)*
- Cortico-steroid therapy : 0.5 mg/kg for 4 wks



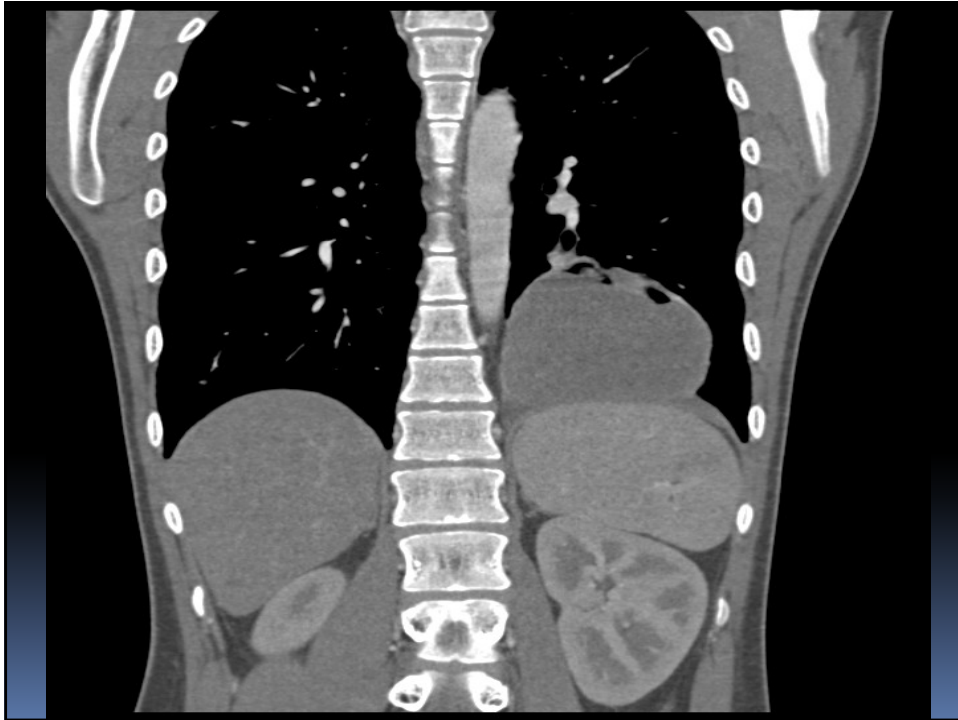
## CASE No 2

- 17 yrs old male patient
- Fever , cough and weight loss over a few months









- Referred to Fortis hospital (Delhi)
- Operated for left lung mass
- Histology : ???

Dx : Undifferentiated large cell  
lung carcinoma

Diagnosis of exclusion :

No features of glandular (adenoc), squamous  
nor small cell differentiation









